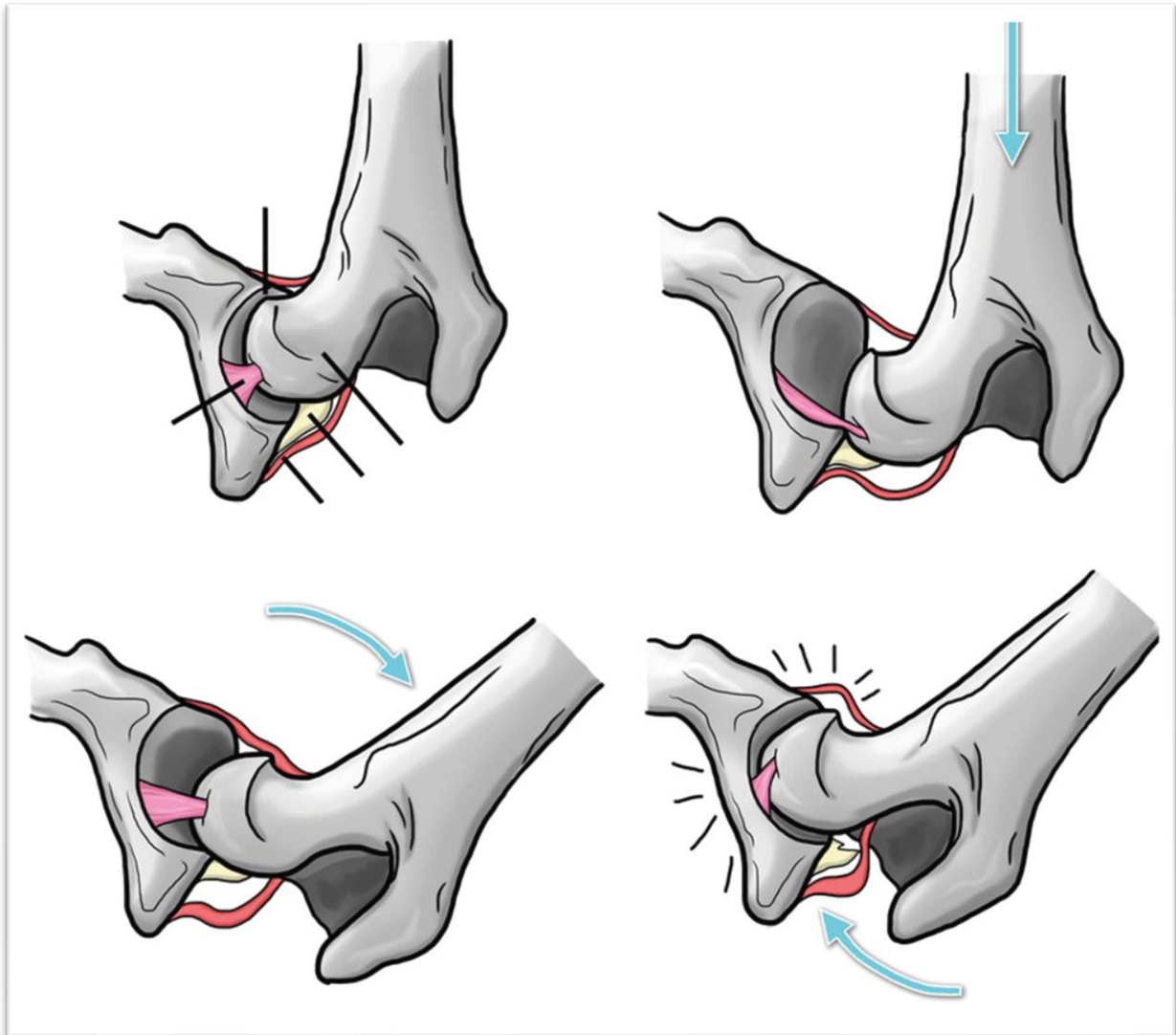


## Performing the Ortolani test

The following illustration shows how to perform the Ortolani test, which checks for hip subluxation in dogs with hip laxity. This is a useful procedure to perform routinely when a patient is under general anaesthesia, when imaging the coxo-femoral joints due to hip pain.



- The first image (top left) shows the coxo-femoral joint prior to distraction.
- The second image (top right) shows what happens when a force is applied from the stifle towards the hip, along the axis of the femur to displace the femoral head.
- The third image (bottom left) shows the femur being abducted so that the joint is reduced.
- The fourth image (bottom right) shows the femoral head popping back into place with an audible clunk, i.e. the Ortolani sign.

The arrows indicate the direction of the applied force.